



**PATIENT**

Lucy DeRemer

**SPECIES**

Canine

**BREED**

Retriever Mix

**SEX**

Female Spayed

**AGE**

7.8 years

**WEIGHT**

42.3lbs

**INTERPRETED BY**

Maggie Machen Lamy,  
DVM, DACVIM  
(Cardiology)

**IMAGING PERFORMED BY**

Tom McNeill

**HOSPITAL NAME**

SVS Imaging CT

**REFERRING VET**

Dr. Meyers

**INVOICE**

23268

**DATE**

3/24/22

**PRESENTING CLINICAL SIGNS**

History: History of cough when excited. Grade 3/6 murmur ausculted. Placed on short course of steroids on 3/10/21.

-Sedated with Butorphanol and Midazolam.

-Radiograph interpretation (3/9/22): The cardiac silhouette appears mildly tall with very slight dorsal deviation of the trachea, but otherwise normal in margination. The pulmonary vessels do not appear overly dilated. Mild bronchointerstitial pattern in the caudodorsal lungs on lateral. No evidence of pulmonary edema at this time.

**ECHOCARDIOGRAM FINDINGS**

2D, m-mode, color flow and doppler imaging is available. Mild diffuse thickening of mitral valve leaflets with no prolapse into the left atrial lumen. Mild eccentric mitral regurgitation with no left atrial dilation. Normal LV diameter with adequate myocardial function. The tricuspid valve appears mildly thickened with trace tricuspid regurgitation. Normal velocity. Normal right atrial and ventricular diameter and morphology indicating no overt evidence of pulmonary arterial hypertension. The pulmonic and aortic valves are normal in morphology and mobility. Normal pulmonic and aortic outflow velocities with laminar flow. No obvious aortic or pulmonic insufficiency. No pericardial or pleural effusion noted. No obvious cardiac masses.

**CARDIAC CHART**

CANINE CARDIAC PARAMETERS	MR VMAX (m/s)	TR VMAX (m/s)	LA/AO (Boon method)	LA/AO (Heart Base; Swe)	FS (%)	EF (%)	EPSS (cm)
NORMAL PARAMETER	4.5-5.5	<2.7	1.3	<1.6	28-40	40-100	<0.6
PATIENT	NM	2.0	NM	1.2	33	60	0.6
CANINE CARDIAC PARAMETERS	HR (BPM)	AV VMAX (m/s)	PV MAX (m/s)	BODY WEIGHT (kg)	LA 2D short axis Base view (cm)	LVIDd Avg; 2D and m-mode short axis (cm)	LVIDs Avg; 2D and m-mode short axis (cm)
NORMAL PARAMETER	50-100	0.7-1.7	0.7-1.6	BELOW	BELOW	BELOW	BELOW
PATIENT	NM	0.95	0.7	19.2	2.3	3.9	2.6
*Normal chamber parameters expressed as a mean value (SD)							
<b>BODY WEIGHT DEPENDENT PARAMETERS</b>							
*Note: All measurements based upon multi-modal images and methods. An average value is reported.							
Adapted from June Boon, Veterinary Echocardiography, 1998 Rishniw M and Hollis NE, J Vet Intern Med 2000; 14:429-435 Hansson et al, Vet Rad and Ultrasound 2002 Bonagura et al. Echocardiography: principles of interpretation, Vet Clin North Am 15:1177, 1995				3	1.27 (5.3)	2.46 (2.46)	1.36 (5.5)
				5	1.40 (4.5)	2.74 (5.2)	1.60 (4.7)
				10	1.50 (3.8)	3.27 (3.5)	2.06 (3.1)
				15	1.83 (2.0)	3.71 (2.4)	2.43 (2.1)
				20	2.02 (1.9)	4.14 (2.2)	2.80 (2.0)
				25	2.18 (2.4)	4.48 (2.9)	3.10 (2.5)
				30	2.33 (3.3)	4.83 (3.9)	3.39 (3.4)
				35	2.48 (4.3)	5.17 (5.0)	3.69 (4.5)
				40	2.62 (5.2)	5.48 (6.1)	3.96 (5.4)
				50	2.88 (7.1)	6.07 (8.3)	4.46 (7.4)

**INTERPRETATION OF THE FINDINGS & FURTHER RECOMMENDATIONS**

Chronic degenerative valve disease causing mild mitral and trace tricuspid regurgitation. Lack of significant left atrial enlargement indicates the current risk for complication is low. No concurrent issues such as systolic dysfunction or pulmonary hypertension are noted in this study. An arrhythmia is noted throughout the study and a baseline ECG is recommended.

**PATIENT**

Lucy DeRemer

Given these findings, the cough is unlikely to be cardiac in origin and primary respiratory causes should be considered. Consider further respiratory work up/treatment (hydrocodone, taper course of steroids, Enrofloxacin, TTW/BAL, etc.).

**SPECIES**

Canine

In a dog with no significant left atrial enlargement, no cardiac medications are clearly indicated. Assessment of progression in the future will help predict long term prognosis, which is highly variable at this stage (B1). Omega fatty acid supplementation and mild salt restriction may be of some long-term benefit. Monitor for development of a cough, labored breathing, exercise intolerance or collapse episodes.

**BREED**

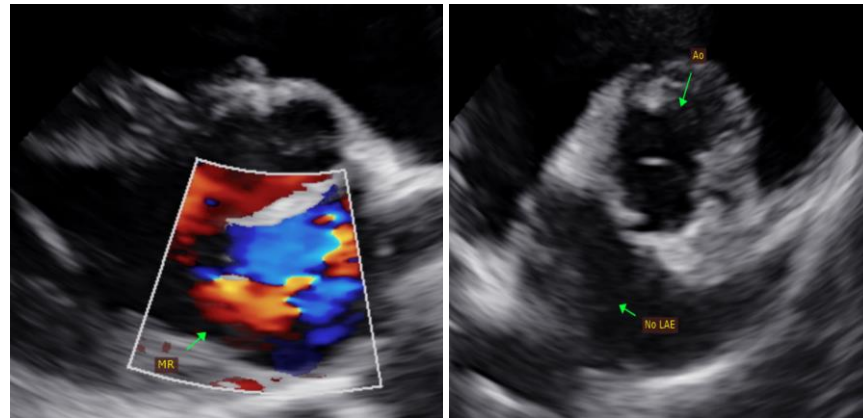
Retriever Mix

No cardiac contraindication to general anesthesia prior to chamber enlargement.

Recommend conservative monitoring with a recheck echocardiogram in 6-12 months, sooner if any development of clinical signs.

**SEX**

Female Spayed

**IMAGES****AGE**

7.8 years

**WEIGHT**

42.3lbs

**INTERPRETED BY**

Maggie Machen Lamy,  
DVM, DACVIM  
(Cardiology)

**The information and recommendations provided are based on the images presented by the referring veterinarian. No evaluation can be communicated regarding pathology that was not visible in the image/video clips provided.**

**IMAGING PERFORMED BY**

Tom McNeill

Thank you for this referral. If the clinical or image interpretation does not parallel your findings or if I can be of any further assistance, please contact me.

**HOSPITAL NAME**

SVS Imaging CT

**Maggie Machen Lamy, DVM**  
**Diplomate of the American College of Veterinary Internal Medicine (Cardiology)**  
info@sonopath.com

**REFERRING VET**

Dr. Meyers

**INVOICE**

23268

**DATE**

3/24/22